

Epidural Stimulation Surgery / T5-T6, UK

Patient Case Report
#ES180019 / 1 Year

Patient Overview

Age: 28

Sex: Male

Nationality: British

Diagnosis on Admission: Spinal Cord Injury, T5-T6 Complete

Treatment Received: Epidural Stimulation Surgery, Medtronic Restore Advance 16-electrode MRI Compatible Device. MSCs and hAFSCs 120 million.

Date of Admission: 01/04/2018

Date of Discharge: 05/05/2018

Patient's Condition on Admission

Patient sustained a complete T5-6 fracture-dislocation spinal cord injury in 2014 with subsequent partial spinal cord transection and myelomalacia. Patient has minimal motor or sensory function below injury level and is suffering from neurogenic bladder and bowel. Patient does not experience severe spasms or spasticity and does not suffer from neuropathic pain. Patient is independent in his daily activities.

Treatment Received

After a Spinal MRI scan, EMG, and comprehensive blood work, patient underwent Laminectomy and implantation of the Epidural Stimulation device on April 2, 2018. The surgery was completed without significant adverse events and no serious complications were reported during the postoperative hospital stay.

Device Mapping and therapy were carried out after surgery for 35 days, then patient was discharged.

Device Mapping and Therapy

Post-Surgical Care	Total Sessions	Sessions Per Week	Time (Hr) Per Session
Mapping	88	22	1
Physical Therapy	28	7	1
Occupational Therapy	-	-	-

Cytotherapy

Type	Amount	Delivery Method	Number of Applications
MSCs	40 Million	IV Injection	1
hAFSCs	80 Million	Lumbar Puncture Injection	2

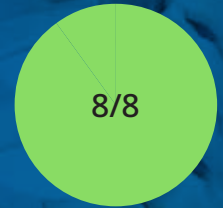


Symptoms Improvement Post-Surgery

Abilities & Symptoms	Motor & Sensory Function (below injury level, before ES surgery)	Improvement Observed (35 days after admission)
Motor Function		
Standing with support	Not Possible	Yes
Stepping with support	Not possible	Yes
Gross motor Skills	Not Present	Yes
Fine Motor skills	Not Applicable	Not Applicable
Balance	Poor	Yes
Coordination	Poor	Yes
Muscle Mass	Low	Yes
Stamina	Low	Yes
Fatigue	Present	Yes
Spasms	Not Applicable	Not Applicable
Spasticity	Not Applicable	Not Applicable
Sensory Function		
Neuropathic pain	Not Applicable	Not Applicable
Bladder Function	No	No
Bowel Function	No	No
Sweating Ability	No	No

Improvements are monitored in 15 targeted areas: 11 Motor areas and 4 Sensory areas. However, the number of targeted areas may vary depending on patient's condition prior to admission. If patient does not experience symptoms in certain Motor/Sensory functions, or is not impaired in a specific targeted area prior to surgery, it is excluded from the report (Not Applicable). If there is progress in any given area -- either mild, moderate, or significant -- it is measured and reported as positive ("Yes"). No improvement, the existence of pain or spasms, or an inability to perform a measured function is reported as "No".

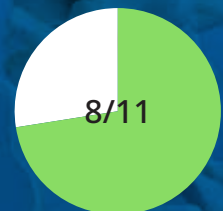Motor Functions



Sensory Functions



Overall Functions



Results Interpretation

Patient is paraplegic with normal upper limb function (Fine Motor skills), and does not experience spasms or spasticity, therefore 8 of 11 Motor Function areas were measured. Motor Function improved in 8 out of 8 targeted areas when the Epidural Stimulation device was switched on. Patient does not suffer from neuropathic pain, therefore 3 of 4 Sensory Function areas were measured. Patient has not experienced any changes in the three measured Sensory Function areas, but more feedback will be collected after 3 months to note any improvements made by cytotherapy. Overall, improvements were observed in 8 out of 11 targeted Motor and Sensory Function areas.

Treatment Summary

After Epidural Stimulation surgery, patient received 88 Mapping sessions and 28 physical therapy sessions. Patient also received 120 million: 40 million MSCs and 80 million hAFSCs through one IV injection and two lumbar puncture injections, respectively. All three applications went well without adverse effects and no short-term or acute complications have been reported.

Due to moderate obesity and excessive subcutaneous adipose tissue, the surgical wound at the IPG implantation site healed slowly and required multiple procedures to drain the residual seroma. After the wound healed, Mapping sessions began.

Patient's Gross Motor Skills have improved significantly, including ankle, hip and knee flexion, and knee extension (kicking out) when Epidural Stimulation device is switched on. Patient has good static and dynamic sitting balance and is able to touch his feet and put on his shoes.

Patient's static standing balance is poor and dynamic standing balance non-existent. Muscle mass and endurance were improved upon discharge, and with physical therapy patient was able to lose 20 kg.

Patient did not require a hoist while standing or during stepping exercises. Patient is able to stand at the parallel bar very well with no support. Patient is able to lock his knees with assistance, but is unable to keep them locked for long periods. Patient has good trunk control and bears weight equally on both legs while standing, but struggles to lock his hips.

During stepping exercises, patient was able to lift his feet very well. Patient is able to bear weight equally on both feet, but requires assistance with foot placement. Patient has good coordination in both legs when stepping.

There was no noticeable improvement to his neurogenic bladder and bowel. Patient received cytotherapy, therefore we expect to see results in these areas within 3 months time. After 35 days, patient was discharged and will continue his physiotherapy back home.

One Year Follow-Up Assessment

Abilities & Symptoms	Observations (1 Year after discharge)
Motor Functions	
Standing with support	Significant Improvement
Stepping with support	Significant Improvement
Gross motor Skills	Moderate Improvement
Fine Motor skills	Not Applicable
Balance	Significant Improvement
Coordination	Moderate Improvement
Muscle Mass	Moderate Improvement
Fatigue	Mild Improvement
Stamina	Significant Improvement
Spasms	Not Applicable
Spasticity	Not Applicable
Sensory Functions	
Neuropathic pain	Not Applicable
Bladder Function	Significant Improvement
Bowel Function	Mild Improvement
Sweating Ability	No change

One-Year Follow-Up Summary

One year after the Epidural Stimulation device was implanted and cytotherapy, patient has been participating in 4 to 5 hours of physical therapy per week.

The programs provided by UAM for gross motor functions have been successful. Patient's gross motor functions such as flexing and extending his ankles, hips and knees have improved moderately. Patient feels stronger and is able to complete more repetitions kicking and pushing out his legs. On a scale of 1-5, 1 being worse than before surgery and 5 being significantly better, patient rates his gross motor functions as a 2.5 to 3.

Patient has noticed significant improvement during standing exercises. He is able to stand up straight and lock both his knees very well. Patient states that he has weak lower back and requires assistance when straightening his spine.

Patient has noticed significant improvement during stepping exercises. He is able to lock both his knees, and keep them locked while taking steps. Patient is able to lift his legs while taking steps and does not require assistance with foot placement. He has good trunk control and is able to bear weight equally on both legs during stepping exercises. Previously, patient was able to take just four steps, but now he can take 10 steps forward, and with better coordination than before.

Patient's static and dynamic standing balance have improved significantly. He is able to stand and move side to side with weights during his physical therapy, and he also reports that he can change from a supine position to sitting position with minimal assistance: he requires assistance to move from supine to 45 degrees, then he is able to sit up by himself. Patient was not able to do this when he was at UAM during his post-operative therapy.

Patient reports an increase in muscle mass, and he feels stronger during therapy sessions. His stamina has improved significantly, and he reports a slightly less fatigue. Patient has lost 25 to 30 kgs since the stem cell injections and Epidural Stimulation device implantation, which makes him feel healthier and happier.

Patient has reported increased sensation from his left abdominal area down his left leg. Patient has also regained bladder sensation and control and is able to hold his bladder contents for longer periods of time. He now only requires a catheter when taking long trips. Patient noticed very mild improvement in bowel functions. He does not have sensation in his bowel area, but is able to empty his bowel better and faster.

Overall, patient is very satisfied with the Epidural Stimulation device and the cytotherapy he received at UAM. Patient would like to return for further cytotherapy and mapping sessions to have minor adjustments made to a few of his programs.

Patient states ***"I am fortunate and very happy with my outcomes and would recommend to anyone this treatment. I look forward to visiting Thailand again for further Cytotherapy and mapping sessions."***



For more information please contact:



Thailand office:

111 Naradhiwas Rajanagarindra 7 Alley,
Khwaeng Thung Maha Mek, Khet Sathon,
Krung Thep Maha Nakhon 10120,
Bangkok, Thailand

<https://uniqueaccess.com>

<https://epiduralstimulationnow.com>

Telephone:

+66 (0) 2 287 2056 TH
+1 888-557-5988 Toll Free USA
+61 2 8310 7389 AUS
+44 20 3868 1498 UK

E-Mail:

info@epiduralstimulationnow.com