

Epidural Stimulation Surgery / T7-T8, Romania

Patient Case Report
#ES180040

Patient Overview

Age: 22

Sex: Male

Nationality: Romanian

Diagnosis on Admission: Spinal Cord Injury, T7-T8

Treatment Received: Epidural Stimulation Surgery, Medtronic Restore Advance 16-electrode MRI Compatible Device.

Date of Admission: 29/07/2018

Date of Discharge: 28/08/2018

Patient's Condition on Admission

Patient sustained a complete T7-T8 spinal cord injury characterized by complete loss of motor and sensory functions below the injury level. Patient endures mild spasticity and spasms, but does not suffer neuropathic pain and has normal sweating ability. Patient is paraplegic with normal upper limb functions and is independent in his daily activities.

Treatment Received

After a Spinal MRI scan and comprehensive blood work, patient underwent Laminectomy and implantation of the Epidural stimulation device on July 30, 2018. The surgery was completed without issue and no serious complications were reported during the postoperative hospital stay. Surgical wounds healed normally and no spinal cord or superficial wound infection was reported.

Device Mapping and therapy were carried out after surgery for 35 days, then patient was discharged.

Post-Surgical Care	Total Sessions	Sessions Per Week	Time (Hr) Per Session
Mapping	84	17	1
Physical Therapy	25	5	1
Occupational Therapy	-	-	-

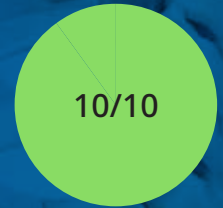


Symptoms Improvement Post-Surgery

Abilities & Symptoms	Motor & Sensory Function (below injury level, before ES surgery)	Improvement Observed (35 days after admission)
Motor Function		
Standing with support	Not Possible	Yes
Stepping with support	Not possible	Yes
Gross motor Skills	Not Present	Yes
Fine Motor skills	Not Applicable	Not Applicable
Balance	Poor	Yes
Coordination	Poor	Yes
Muscle Mass	Low	Yes
Stamina	Low	Yes
Fatigue	Present	Yes
Spasms	Present	Yes
Spasticity	Present	Yes
Sensory Function		
Neuropathic pain	Not Applicable	Not Applicable
Bladder Function	No	No
Bowel Function	No	No
Sweating Ability	Not Applicable	Not Applicable

Improvements are monitored in 15 targeted areas: 11 Motor areas and 4 Sensory areas. However, the number of targeted areas may vary depending on patient's condition prior to admission. If patient does not experience symptoms in certain Motor/Sensory functions, or is not impaired in a specific targeted area prior to surgery, it is excluded from the report (Not Applicable). If there is progress in any given area -- either mild, moderate, or significant -- it is measured and reported as positive ("Yes"). No improvement, the existence of pain or spasms, or an inability to perform a measured function is reported as "No".

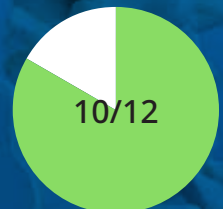Motor Functions



Sensory Functions



Overall Functions



Results Interpretation

For this patient, 12 areas instead of 15 were reviewed. Fine Motor Skills were normal prior to his Epidural Stimulation surgery, so it was not measured by UAM. Patient also does not suffer from neuropathic pain and has normal sweating ability, therefore these areas have also been excluded from the report. Motor Function improved in 10 out of 10 targeted areas, but the patient has not experienced any changes in Sensory Function.

Treatment Summary

After Epidural Stimulation Surgery, patient received 84 Mapping sessions and 25 Physical Therapy sessions. Surgery and therapy went well without adverse effects and no short-term or acute complications have been reported.

Patient's Gross Motor Skills have improved significantly, including in his ankles, knee extension (kicking and pushing out), and hip and knee flexion. Patient is able to sit up straight with normal static balance, and his dynamic sitting balance has improved.

When standing and stepping with support, patient did not require a hoist and was able to use a walking frame and parallel bars. When patient is standing he requires assistance in locking his hips and knees. Patient has good trunk control while standing and is able to bear weight equally on both legs. Patient is able to stand at the parallel bars with some assistance.

When stepping, patient uses a walking frame and is able to lift both feet, but the left side is better than the right. Patient has very good coordination between left and right feet when taking steps. When taking short steps, patient does not require assistance in foot placement, but does when taking longer steps.

Patient's muscle mass has increased and endurance has improved significantly. Extensor spasms have decreased, but patient still experiences flexor spasms with the same frequency as before surgery.

There was no noticeable change in bladder and bowel function. After 35 days, patient was discharged and will continue his physiotherapy back home.



For more information please contact:



Thailand office:

111 Naradhiwas Rajanagarindra 7 Alley,
Khwaeng Thung Maha Mek, Khet Sathon,
Krung Thep Maha Nakhon 10120,
Bangkok, Thailand

<https://uniqueaccess.com>
<https://epiduralstimulationnow.com>

   [epiduralstimulationnow](https://epiduralstimulationnow.com)

Telephone:

+66 (0) 2 287 2056 TH
+1 888-557-5988 Toll Free USA
+61 2 8310 7389 AUS
+44 20 3868 1498 UK

E-Mail:

info@epiduralstimulationnow.com

 [@SCIBreakthrough](https://twitter.com/SCIBreakthrough)